ELSEVIER
SAUNDERS

Orthop Clin N Am 36 (2005) 187 – 193

ORTHOPEDIC
CLINICS
OF NORTH AMERICA

Complications Associated with Hip Resurfacing Arthroplasty

A.J. Shimmin, MBBS, FRACS, Dip Anat*, J. Bare, MBBS, FRACS, D.L. Back, FRCS(Edin)(Orth)

The Melbourne Orthopaedic Group, 33 The Avenue Windsor, 3181 Melbourne, Australia

Hip resurfacing arthroplasty is an old orthopedic concept that has undergone a resurgence of interest in the past decade [1–8]. Previous problems associated with thin polyethylene acetabular components, reproducible quality of manufacturing of metal-on-metal implants, and component fixation issues appear to have been resolved and a more reliable prosthesis developed [4,8,9].

The proposed advantages of hip resurfacing over conventional total hip arthroplasty are bone conservation, reproduction of anatomic hip biomechanics, greater implant stability, and assumed easier revision procedures.

There are no long-term results available on the new-generation hip resurfacing arthroplasties. Studies of the Conserve Plus (Wright Medical Technology, Arlington, Tennessee), the McMinn and Cormet (Corin Medical, Cirencester, UK), and the Birmingham Hip Resurfacing (Midland Medical Technologies, Birmingham, UK) have a mean of 3 years' follow-up demonstrating survivorship of >97% [1,2,10]. These studies demonstrate significantly better survivorship than previous generations of hip resurfacing prostheses (eg, Wagner, Imperial College London Hospital (ICLH), THARIES, Furaya) [1,6,7]. The most popular prosthesis currently in use is the Birmingham Hip Resurfacing.

Over the last decade, there has been a rapid increase in the number of procedures being performed, and previously recognized complications have begun to recur; for example, femoral neck fracture [1,6,7]. Our understanding of these problems is continuously evolving, allowing us to better inform patients of the risks and allow further development of the technology to try to overcome them [11].

The ideal candidate for a hip resurfacing procedure is currently believed to be a young (<60 years) active man with normal proximal femoral bone geometry and bone quality who would be expected to outlive any current conventional prosthesis. Preoperative diagnoses can be varied and include osteoarthritis, osteonecrosis, and degenerative conditions secondary to developmental hip dysplasia, slipped capital femoral epiphysis, and Legg-Calvé-Perthes disease.

Contraindications for a resurfacing procedure are still being defined. Currently, absolute contraindications include elderly people with osteoporotic proximal femoral bone, known metal hypersensitivity, and impaired renal function. Relative contraindications include inflammatory arthropathies, severe acetabular dysplasia, grossly abnormal proximal femoral geometry (as may be encountered with some severe cases of Legg-Calvé-Perthes and slipped capital femoral epiphysis), large areas of avascular necrosis, and large geode formation (Fig. 1).

Problems that have been encountered can be divided into two main groups: (1) those associated with any type of hip arthroplasty; for example, dislocation, thromboembolic disease, heterotopic ossification, nerve palsies, and vascular damage; and (2) those that are more specifically related to the hip resurfacing procedure and the focus of this article; namely, femoral neck fractures, avascular necrosis, raised

* Corresponding author.
E-mail address: ashimmin@optusnet.com.au (A.J. Shimmin).

doi:10.1016/j.ocl.2005.01.002

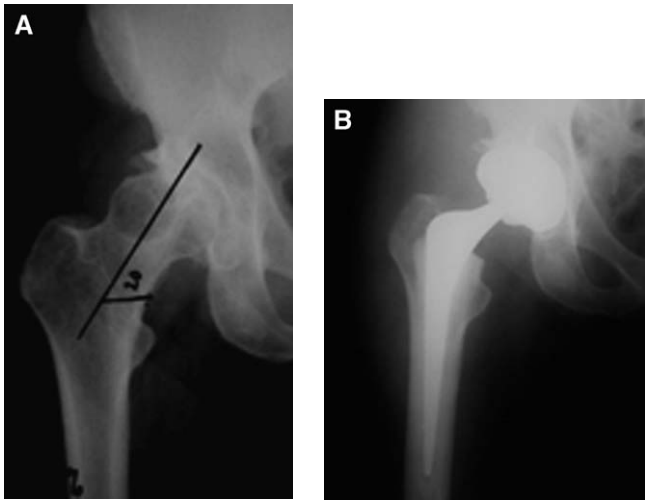

Fig. 1. (*A*) A case deemed unsuitable for hip resurfacing due to a large femoral head cyst that would compromise femoral component fixation and mechanics. (*B*) Postoperative radiograph.

metal ion levels, and sound initial and durable long-term fixation of an all-metal monoblock cobalt/chrome acetabular component.

Femoral neck fracture

Retention of the femoral neck exposes the patient to the risk of femoral neck fracture in the immediate postoperative period and in the future as per the general aging population.

A recently conducted multisurgeon national audit of the first 3429 Birmingham Hip Resurfacings, performed over a 4-year period, demonstrated a femoral neck fracture rate of 1.46% (50 cases). The fate of all inserted prostheses was known. Mean time to fracture was 15.4 weeks (range 0–56 weeks) [12]. Important patient, surgical, and postoperative factors with regard to the risk of fracture were identified from this review.

Patient factors

Patient factors included sex and proximal femoral bone quality. The national fracture rate was 0.98% for men and 1.91% for women undergoing hip resurfacing. This difference was statistically significant (χ^2 test: $P < 0.001$); that is, women were twice as likely to fracture as men. No conclusions could be drawn with regard to the optimum age range for a hip resurfacing from this audit. It may be postulated, however, that the decrease in bone density in postmenopausal women may have been a factor [12].

Surgical factors

Surgical factors associated with an increased risk of femoral neck fracture included notching of the superior femoral neck cortex (Fig. 2) combined with varus placement of the femoral component relative to the anatomic femoral neck shaft angle. In this series, 26 of 50 cases demonstrated notching of the femoral neck on the postoperative radiograph and 42 of 50 cases had a varus-placed femoral prosthesis [12,13].

When consenting the patient for a hip resurfacing procedure, it is advisable to also consent for a total hip arthroplasty. If problems are encountered with alignment, notching, or large geode formation, then conversion to a conventional hip arthroplasty is an option.

This evidence is consistent with known biomechanical considerations as proposed by Freeman [13] and knowledge gained from a recent retrospective biomechanical and clinical analysis [14] of 94 hips with a mean follow-up of 4.2 years. The resultant force vectors borne by the femoral head during walking encounter the femoral head at an angle of approximately 20° to the vertical in the frontal plane. The medial trabecular system lies in this axis. It has been shown that the strongest bone in compression is that of the medial trabecular system, whereas the bone in the head medial to this system is weak.

Hence, in the varus position, (1) tensile stresses appear in the bone of the lateral surface of the neck as it enters the prosthesis, (2) the medial compressive stresses rise considerably, and (3) sheer stresses develop at the mouth of the prosthesis [11].

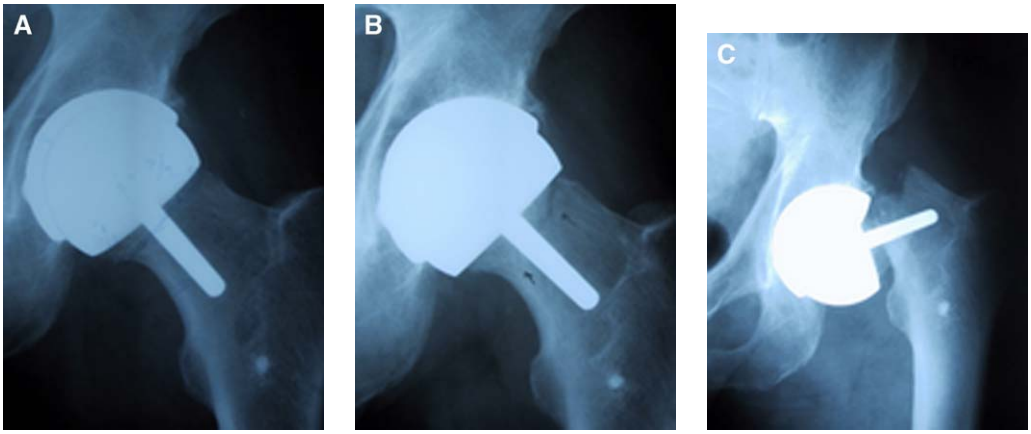

Fig. 2. (*A*) Postoperative radiograph of a femoral head prepared with a notch in the superior neck that may have contributed to the propagation of a fracture as seen evolving 6 weeks post surgery (*B*) and 10 weeks post surgery (*C*).

Postoperative factors

All patients in this national audit [12] were instructed to mobilize fully weight bearing postoperatively. Because the femoral neck undergoes a considerable surgical insult from intramedullary instrumentation, cylindrical reaming, and chamfer cutting, it may be reasonable to surmise that this treatment results in a "stressed" femur. A period of protected weight bearing postoperatively may reduce any tendency to fracture, particularly if notching of the femoral neck has occurred.

Avascular necrosis of the femoral head

In theory, preparation of the femoral head could cause avascular necrosis, which could ultimately lead to failure of the prosthesis due to loosening or periprosthetic fracture. Freeman [13] believed that the arthritic hip undergoes changes in the vascular supply of the femoral head, with the blood supply being predominantly intraosseous in arthritic hips rather than subsynovial vessels [11]. Current studies report a low incidence of avascular necrosis as a cause of implant failure at a mean of 3 years [1–3]. Studies on isolated primary hemiresurfacing of the femoral head report an absence of avascular necrosis on retrieval specimens [15]. These series appear to support Freeman's [13] theories.

The choice of surgical approach is theoretically an issue in the development of avascular necrosis. Traditionally, the posterior approach has been the most commonly used. This approach sacrifices the ascending branch of the medial femoral circumflex artery, which is an important contributor to the subsynovial supply of the normal femoral head. More recently, some surgeons have adopted the direct lateral or the surgical dislocation approach popularized by Ganz et al [16,17].

Other possible reasons for the small incidence of avascular necrosis with resurfacing procedures may reflect that it is the neck rather than the head that is being resurfaced. Considering that the technique involves resecting a portion of the zenith of the head and pressurizing cement for several millimeters into the prepared surface, it may be that there is not much remaining of the bone proximal to the fused epiphyseal plate. This allows us to conclude that it is the intraosseous femoral neck blood supply that is of paramount importance.

Metal ion levels

Hip resurfacing has the requirement to produce a thin acetabular shell of between 3 and 5 mm. This measurement limits the material of choice to metal-on-metal bearings.

Metal-on-metal bearings have been used in orthopedic surgery for the hip for the past 40 years and there have been no conclusive studies to suggest that they cause any adverse long-term effects (ie, carcinogenesis) [18–22]. It is known that metal-on-metal bearings produce higher serum cobalt and chromium levels than conventional metal-on-polyethylene bear-

ings. Numerous articles have shown elevation of metal ion levels in metal-on-metal articulations compared with other articulations [23–26]; however, it is difficult to compare series because they measure different combinations of parameters (serum, blood, erythrocyte, and urine) using different measurement techniques. These different techniques have a wide range of sensitivities and baseline measurements. In addition, the significance of these elevated levels is not known.

Recent prospective studies of the Birmingham Hip Resurfacing have shown that serum cobalt levels rise to a peak at 6 months post procedure and are still declining at 3 years. The chromium levels peak at 9 months and then begin to decline. In these patients, no clinical issues appear to relate to the serum ion elevation in the short-term [27]; however, sporadic cases of hypersensitivity are being seen. Whether this is a true hypersensitivity response or a capsular response to a toxic local concentration of metal ion is unclear [28,29].

Hallab's [30–33] metal sensitivity work suggests that (1) the incidence of dermatologic sensitivities to metals in arthroplasty patients is higher than in the general population; (2) the risk of sensitivity to orthopedic implants is minimal and it is unclear whether metal sensitivity contributes to implant failure; and (3) preoperative dermatologic screening for metal hypersensitivity (delayed-type) is unreliable for predicting the response to a metallic prosthesis.

Currently, there is no reliable hematologic preoperative test to predict hypersensitivity, although work is being done on the development of lymphocyte reactivity tests to the alloy used in these implants [30–33].

The new generation of hip resurfacings are all formed from cobalt/chrome alloys. Different implants vary subtly in design and manufacturing processes. Whether implant manufacturing issues (ie, cast versus wrought cobalt/chromium, heat treating versus no heat treating, or variations in radial clearance) will influence the incidence of hypersensitivity/toxicity responses will become apparent with more detailed long-term follow-up of these implants [34].

The issues surrounding metal ion levels can be removed as a concern when ceramic bearings can be manufactured in the required dimensions.

Acetabular component fixation

In the absence of wear particles generating osteolysis, femoral component failure and loosening may result from fracture or avascular necrosis. Issues surrounding acetabular component aseptic loosening are somewhat different.

Initial reports on a pilot study by McMinn et al [2] that compared different forms of fixation in hip resurfacing arthroplasty found that hydroxyapatite-coated acetabular components gave the best clinical and radiographic outcomes. More recent reports on the results of the McMinn hybrid resurfacing and the Birmingham Hip Resurfacing arthroplasty have a mean follow-up of 3.3 years (range, 1.1–8.2 years) [3]. There are 446 hips in this series, and so far, there have been no reported acetabular-related failures. Amstutz et al [1] also recently published a series of 400 Conserve Plus hips. This group has an average follow-up of 3.5 years (range, 2.2–6.2 years). Only

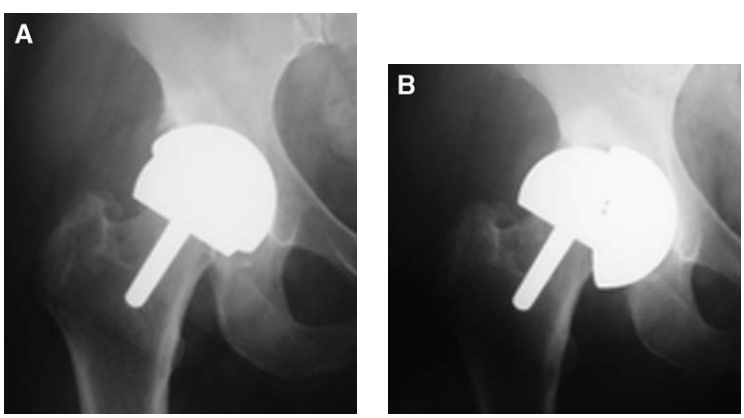

Fig. 3. (*A*) Radiograph taken 12 months post implantation. The patient was fully functional and very happy. (*B*) Radiograph taken 18 months post implantation when the patient presented with acute onset of groin pain after rising from a chair.

one hip (0.3%) has been revised for early failure of the acetabular component; however, a 32% rate of radiolucency (26% in one zone, 6% in two zones) was also reported. The clinical significance of these findings remains to be seen.

Good long-term success has been reported with cementless acetabular fixation in total hip arthroplasty [35–37]. Aseptic failures of these cups have largely been attributed to osteolysis from high volumetric polyethylene wear debris, a problem theoretically reduced by removing polyethylene from resurfacing arthroplasty [5]. A number of differences exist between the acetabular component of a total hip arthroplasty and that of a resurfacing arthroplasty that could lead to poorer results in the resurfacing group:

1. All modern hip resurfacing arthroplasties use a solid cobalt/chromium cup of between 3 and 5 mm thickness. Theoretically, because titanium is more biocompatible and has a modulus of elasticity closer to bone than cobalt/chromium, it should allow greater osseointegration. Therefore, most cementless total hip replacement systems use titanium as the ingrowth surface for the acetabular component [38–42]. Whether concern about biologic fixation of cementless cobalt/chromium cups is a theoretic rather than practical problem will evolve with ongoing long-term clinical review of large series (Fig. 3).
2. The inability to place screws behind the bearing surface increases the requirement to attain a secure initial press-fit fixation. To limit this potential problem, some resurfacing acetabular components provide supplementary fixation in the form of fins, peripheral expansion, or cups with peripheral screw holes such as the Birmingham dysplasia cup.

Other complications

Due to the larger-sized femoral component and because of restoring anatomic hip biomechanics, the rate of dislocation of a hip resurfacing prosthesis appears to be significantly less than that of a conventional total hip arthroplasty [43]. Published dislocation rates are 0.75% at a mean of 3 years' follow-up. In an initial series of 231 cases, there were no dislocations [1,3,44].

The reported rates of deep venous thrombosis, pulmonary embolus, heterotopic bone, and intraoperative nerve and vessel injury [44] are comparable with traditional arthroplasty techniques.

Summary

Hip resurfacing surgery is an evolving field in orthopedics. The complications discussed can be summarized as having a combination of causes. Surgical factors are undoubtedly important and involve preoperative and intraoperative decision making and surgical technique. Other, less controllable complications are due to biologic and material factors.

Periprosthetic fracture of the femoral neck is the most common complication. Its cause is multifactorial, including patient selection, surgical technique, and postoperative management. Avascular necrosis has occurred but is less frequent than might be expected when using the traditional posterior approach for this procedure. It is thought that the osteoarthritic hip develops a more intraosseous blood supply throughout the course of this disease, placing it at lower risk of developing avascular necrosis subsequent to any resurfacing procedure.

Elevated serum and blood metal ion levels and local tissue toxicity or hypersensitivity are other potential problems of this procedure, which currently still requires the use of a metal-on-metal articulation. Despite a long history of the use of metal-on-metal articulations with no proven adverse clinical consequences, concerns are still expressed with regard to the long-term outcome of elevated serum metal ion levels. There also are some sporadic cases of local hypersensitivity/toxicity. Preoperative lymphocyte reactivity tests may help to predict susceptible individuals in the future.

Aseptic loosening of the acetabular component may occur at later follow-up because of the rigidity of the implant and poorer bone ingrowth at the acetabular interface. Newer designs have titanium surface finishes to theoretically provide better osseous integration of the acetabular component.

Dislocation rates after resurfacing are predictably lower than for conventional 28-mm head total hip replacements due to the larger head size and more accurate restoration of hip biomechanics.

Currently, there are no survivorship figures to assess the long-term prognosis of this procedure, although initial results appear promising. Of the new generation of hip resurfacings, there have been only two short-term (3-year) reviews published, which have come from the designers of the two prostheses [1,3].

There is a need for independent prospective studies to be published in the orthopedic literature to allow better guidance on this procedure. More publications will allow better assessment of complication rates and the suitability of this prosthesis for long-term use.

References

[1] Amstutz HC, Beaule PE, Dorey FJ, et al. Metal-on-metal hybrid surface arthropasty: two to six year follow up study. J Bone Joint Surg [Am] 2004;86(1): 28–39.

[2] McMinn D, Treacy R, Lin K, et al. Metal on metal surface replacement of the hip. Experience of the McMinn prosthesis. Clin Orthop 1996;329S:S89–98.

[3] Daniel J, Pynsent PB, McMinn DJW. Metal on metal resurfacing of the hip in patients under the age of 55 years with osteoarthritis. J Bone Joint Surg [Br] 2004;86:177–84.

[4] Amstutz HC, Dorey FJ, O'Carroll PF. THARIES resurfacing arthroplasty. Clin Orthop 1986;213:92–113.

[5] Amstutz HC, Grigoris P, Dorey FJ. Evolution and future of surface replacement of the hip. J Orthop Sci 1998;3(3):169–86.

[6] Freeman MAR, Cameron HU, Brown GC. Cemented double cup arthroplasty of the hip: a 5 year experience with the ICLH prosthesis. Clin Orthop 1978;134: 45–52.

[7] Furaya K, Tsuchiya M, Kawachi S. Socket cup arthroplasty. Clin Orthop 1978;134:41–4.

[8] Howie DW, Campbell D, McGee M, et al. Wagner resurfacing hip arthroplasty. J Bone Joint Surg [Am] 1990;72:708–14.

[9] August AC, Aldam CH, Pynsent PB. The McKee-Farrar hip arthroplasty. A long term study. J Bone Joint Surg [Br] 1986;68:520–7.

[10] Nevelos J, Ahmad Y, Shelton J. Development, validation and multi-centre follow-up of a modern metal-metal hip resurfacing prosthesis [abstract]. Presented at the AAOS Scientific Exhibition, New Orleans, 2003.

[11] Amstutz HC, Campbell PA, Le Duff MJ. Fracture of the neck of the femur after surface arthroplasty of the hip. J Bone Joint Surg [Am] 2004;86(9): 1874–7.

[12] Shimmin AJ, Back DL. Femoral neck fractures associated with hip resurfacing: a national review of 50 cases. J Bone Joint Surg [Br] 2005, in press.

[13] Freeman MAR. Some anatomical and mechanical considerations relevant to the surface replacement of the femoral head. Clin Orthop 1978;134:19–24.

[14] Beaule PE, Lee JL, LeDuff MJ, et al. Orientation of the femoral component in surface arthroplasty of the hip: a biomechanical and clinical analysis. J Bone Joint Surg [Am] 2004;86(9):2015–21.

[15] Campbell P, Mirra H, Amstutz HC. Viability of femoral heads treated with surface arthroplasty. J Arthroplasty 2000;15(1):120–2.

[16] Ganz R, Gill TJ, Guatier E, et al. Surgical dislocation of the adult hip. J Bone Joint Surg [Br] 2001;83(8): 1119–24.

[17] Beaule PE. A soft tissue sparing approach for surface arthroplasty of the hip. Oper Tech Ortho 2004;14(2): 75–84.

[18] Gillespie WJ, Frampton CM, Henderson RJ, et al. The incidence of cancer following total hip replacement. J Bone Joint Surg [Br] 1998;70(4):539–42.

[19] Gillespie WJ, Henry DA, O'Connell DL, et al. Development of haematopoietic cancers after implantation of total joint replacement. Clin Orthop 1996; 329(Suppl):S290–6.

[20] Mathiesen EB, Ahlbom A, Bermann G, et al. Total hip replacement and cancer. A cohort study. J Bone Joint Surg [Br] 1995;77(3):345–50.

[21] Nyren O, McLaughlin JK, Gridley G, et al. Cancer risk after hip replacement with metal implants: a population based cohort study. J Natl Cancer Inst 1995; 87(1):28–33.

[22] Visuri T, Pukkala E, Paavolainen P, et al. Cancer risk after metal on metal and polyethylene on metal total hip arthroplasty. Clin Orthop 1996;329S:S280–9.

[23] Brodner W, Bitzan P, Meisinger V, et al. Elevated serum cobalt with metal on metal articulating surfaces. J Bone Joint Surg [Br] 1997;79(2):316–21.

[24] Jacobs JJ, Skipor AK, Doorn PF, et al. Cobalt and chromium concentrations in patients with metal on metal total hip replacements. Clin Orthop 1996;329S: 256–63.

[25] Maezawa K, Nowaza M, Hirose T, et al. Cobalt and chromium concentrations in patients with metal on metal and other cementless total hip arthroplasty. Arch Orthop Trauma Surg 2002;122(5):283–7.

[26] Skipor AK, Campbell PA, Patterson LM, et al. Serum and urine metal ion levels in patients with metal on metal surface arthroplsty. J Mater Sci Mater Med 2002; 13(12):1227–34.

[27] Back DL, Young DA, Shimmin AJ. Serum metal ion levels following a hip resurfacing. Clin Orthop, in press.

[28] Jacobs JJ, Hallab NJ, Skipor AK, et al. Metal degradation products: a cause for concern in metal-metal bearings? Clin Orthop 2003;417:139–47.

[29] Doorn PF, Mirra JM, Campbell PA, et al. Tissue reaction to metal on metal total hip prestheses. Clin Orthop 1996;329(Suppl):S187–205.

[30] Hallab NJ, Jacobs JJ, Skipor A, et al. Systemic metal-protein binding associated with total joint replacement arthroplasty. J Biomed Mater Res 2000;49(3):353–61.

[31] Hallab NJ, Mikeez K, Jacobs JJ. A triple assay technique for the evaluation of metal induced, delayed type hypersensitivity responses in patients with or receiving total joint arthroplasty. J Biomed Mater Res 2000;53(5):480–9.

[32] Hallab NJ, Merritt K, Jacobs JJ. Metal sensitivity in patients with orthopaedic implants. J Bone Joint Surg [Am] 2001;83:428–36.

[33] Hallab NJ, Mikeez K, Vermes C, et al. Orthopaedic implant related metal toxicity in terms of human lymphocyte reactivity to metal-protein complexes produced from cobalt-base and titanium base implant alloy degradation. Mol Cell Biochem 2001;222(1–2): 127–36.

[34] Urban RM, Jacobs JJ, Tomlinson MJ, et al. Dissemination of wear particles to the liver spleen and abdominal lymph nodes of patients with hip or

knee replacement. J Bone Joint Surg [Am] 2000;82: 457–76.

[35] Clohisy JC, Harris WH. The Harris-Galante porous coated acetabular component with screw fixation. An average ten year follow up study. J Bone Joint Surg [Br] 2004;86(2):177–84.

[36] Kim YH, Kim JS, Cho SH. Primary total hip arthroplasty with a cementless porous coated anatomic total hip prosthesis: 10–12 yr results of prospective and consecutive series. J Arthroplasty 1999;14(5): 538–48.

[37] Ritter MA, Keating EM, Faris PM, et al. Metal-backed acetabular cups in total hip arthroplasty. J Bone Joint Surg [Am] 1990;72(5):672–7.

[38] Ilgen R, Rubash HE. The optimal fixation of the cementless acetabular component in primary total hip arthroplasty. J Am Acad Orthop Surg 2002;10(1): 43–56.

[39] Kienapfel H, Sprey C, Wilke A, et al. Implant fixation by bone ingrowth. J Arthoplasty 1999;14(3):355–68.

[40] Bourne RB, Rorabeck CH, Burkart BC, et al. Ingrowth surfaces. Plasma spray coating to titanium alloy hip replacements. Clin Orthop 1994;298:37–46.

[41] Smith SE, Estok D, Harris WH. Average 12 yr outcome of a chrome–cobalt beaded bony ingrowth acetabular component. J Arthroplasty 1998;13(1):50–60.

[42] Smith SW, Estok DM, Harris WH. Total hip arthroplasty with use of second generation cementing techniques. An eighteen year average follow up study. J Bone Joint Surg [Am] 1998;80(11):1632–40.

[43] Charnley J. The long-term results of low-friction arthroplasty of the hip performed as a primary intervention. J Bone Joint Surg [Br] 1972;54:61–76.

[44] Back DL, Dalziel R, Young DA, et al. Birmingham hip resurfacing: an independent prospective review of 230 hips. J Bone Joint Surg [Br], in press.